PULPITE MODÉRÉE

GESTION PAR PULPOTOMIE

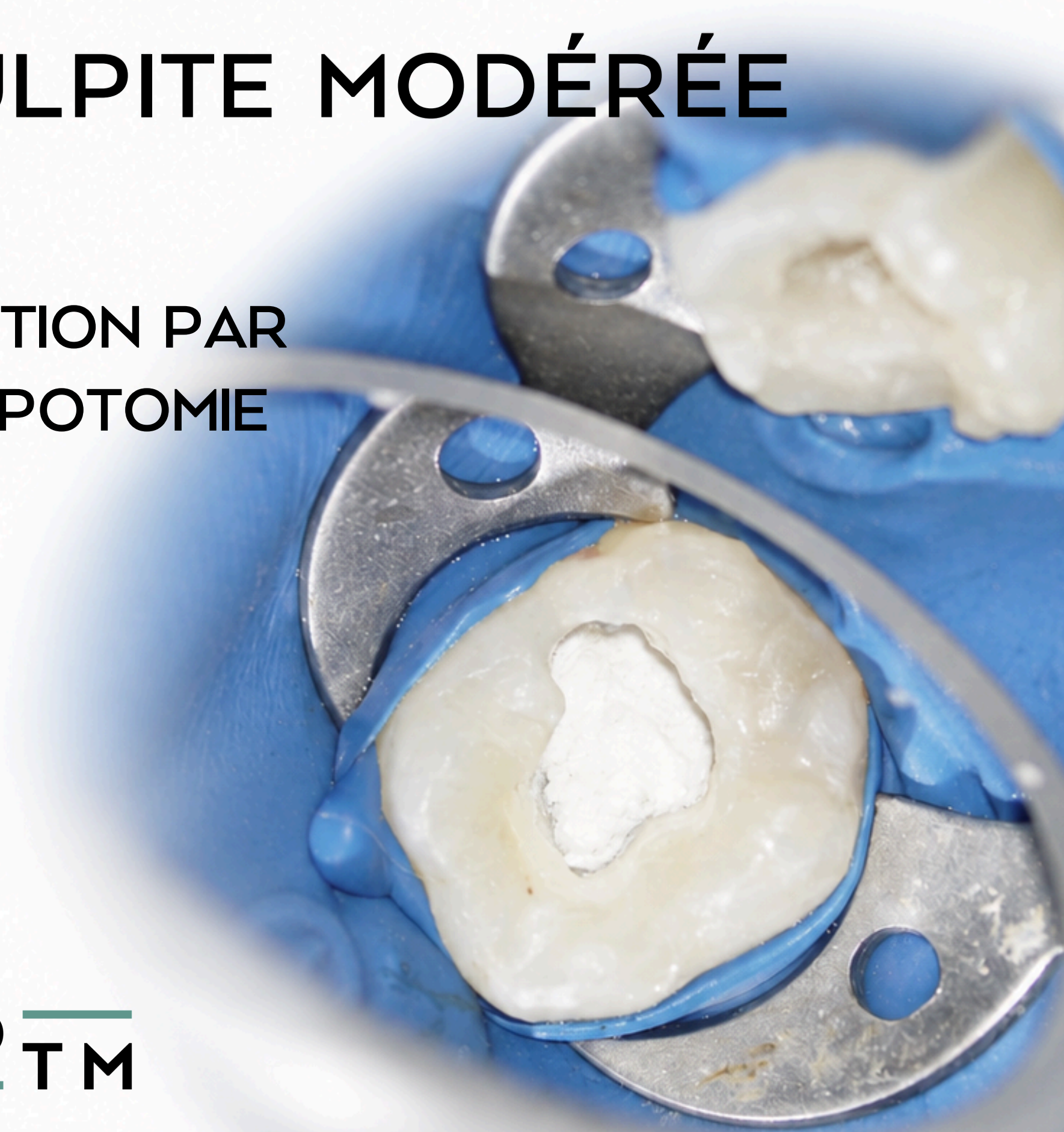

EDTM

DIAGNOSTIC

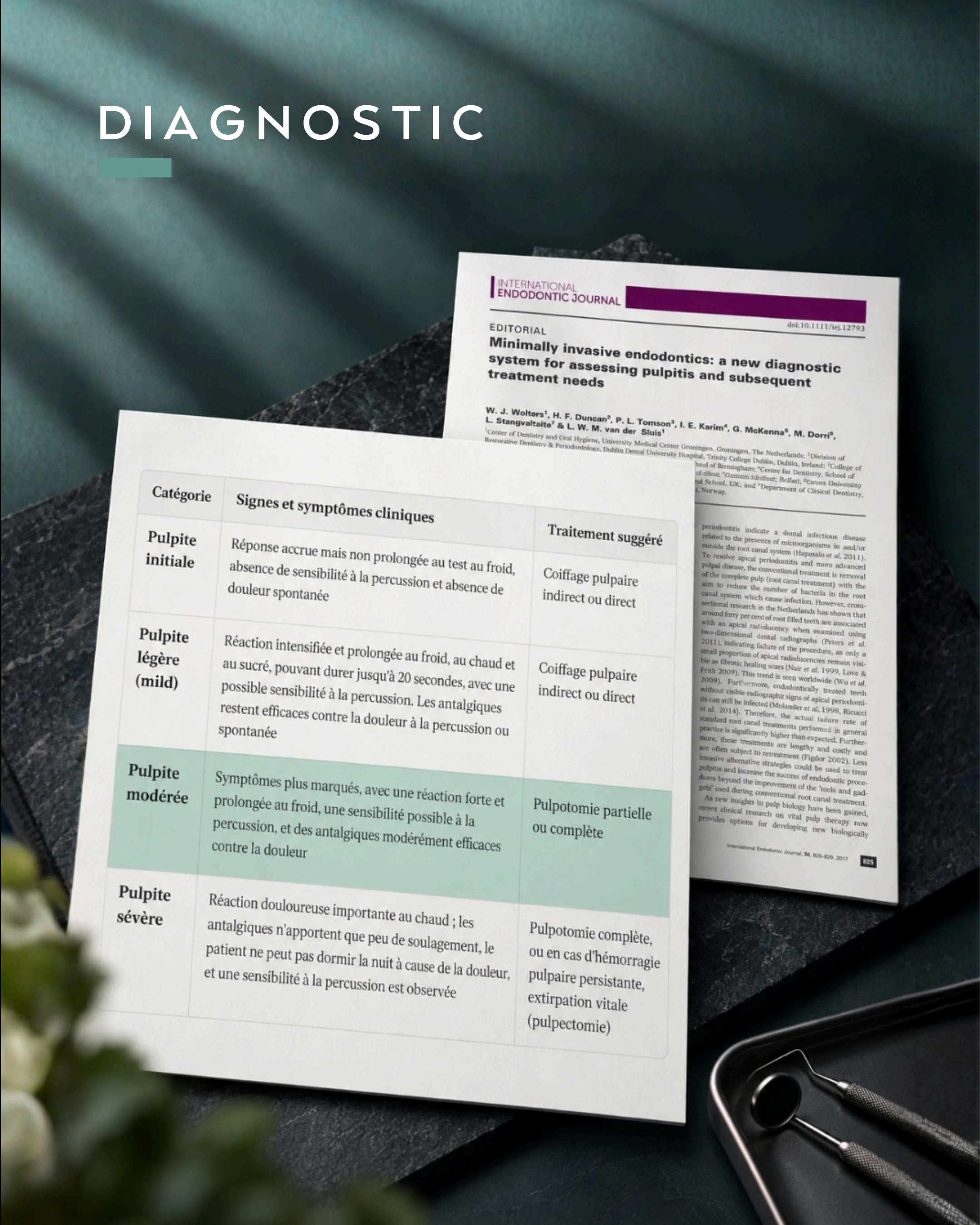

INTERNATIONAL ENDODONTIC JOURNAL

doi:10.1111/iej.12793

EDITORIAL

Minimally invasive endodontics: a new diagnostic system for assessing pulpitis and subsequent treatment needs

W. J. Wolters[1], H. F. Duncan[2], P. L. Tomson[3], I. E. Karim[4], G. McKenna[5], M. Dorri[6], L. Stangvaltaite[7] & L. W. M. van der Sluis[1]

[1]Center of Dentistry and Oral Hygiene, University Medical Center Groningen, Groningen, The Netherlands; [2]Division of Restorative Dentistry & Periodontology, Dublin Dental University Hospital, Trinity College Dublin, Dublin, Ireland; [3]College of ... of Birmingham; [4]Centre for Dentistry, School of ... Belfast; [5]Queen University ... School, UK; and [6]Department of Clinical Dentistry, ... Norway.

periodontitis indicate a dental infectious disease related to the presence of microorganisms in and/or outside the root canal system (Hapasalo *et al.* 2011). To resolve apical periodontitis and more advanced pulpal disease, the conventional treatment is removal of the complete pulp (root canal treatment) with the aim to reduce the number of bacteria in the root canal system which cause infection. However, cross-sectional research in the Netherlands has shown that around forty per cent of root filled teeth are associated with an apical radiolucency when examined using two-dimensional dental radiographs (Peters *et al.* 2011), indicating failure of the procedure, as only a small proportion of apical radiolucencies remain visible as fibrotic healing scars (Nair *et al.* 1999, Love & Frith 2009). This trend is seen worldwide (Wu *et al.* 2009). Furthermore, endodontically treated teeth without visible radiographic signs of apical periodontitis can still be infected (Molander *et al.* 1998, Ricucci *et al.* 2014). Therefore, the actual failure rate of standard root canal treatments performed in general practice is significantly higher than expected. Furthermore, these treatments are lengthy and costly and are often subject to retreatment (Figdor 2002). Less invasive alternative strategies could be used to treat pulpitis and increase the success of endodontic procedures beyond the improvement of the 'tools and gadgets' used during conventional root canal treatment.

As new insights in pulp biology have been gained, recent clinical research on vital pulp therapy now provides options for developing new biologically

Catégorie	Signes et symptômes cliniques	Traitement suggéré
Pulpite initiale	Réponse accrue mais non prolongée au test au froid, absence de sensibilité à la percussion et absence de douleur spontanée	Coiffage pulpaire indirect ou direct
Pulpite légère (mild)	Réaction intensifiée et prolongée au froid, au chaud et au sucré, pouvant durer jusqu'à 20 secondes, avec une possible sensibilité à la percussion. Les antalgiques restent efficaces contre la douleur à la percussion ou spontanée	Coiffage pulpaire indirect ou direct
Pulpite modérée	Symptômes plus marqués, avec une réaction forte et prolongée au froid, une sensibilité possible à la percussion, et des antalgiques modérément efficaces contre la douleur	Pulpotomie partielle ou complète
Pulpite sévère	Réaction douloureuse importante au chaud ; les antalgiques n'apportent que peu de soulagement, le patient ne peut pas dormir la nuit à cause de la douleur, et une sensibilité à la percussion est observée	Pulpotomie complète, ou en cas d'hémorragie pulpaire persistante, extirpation vitale (pulpectomie)

DÉCISION THÉRAPEUTIQUE

Pulpotomie camérale

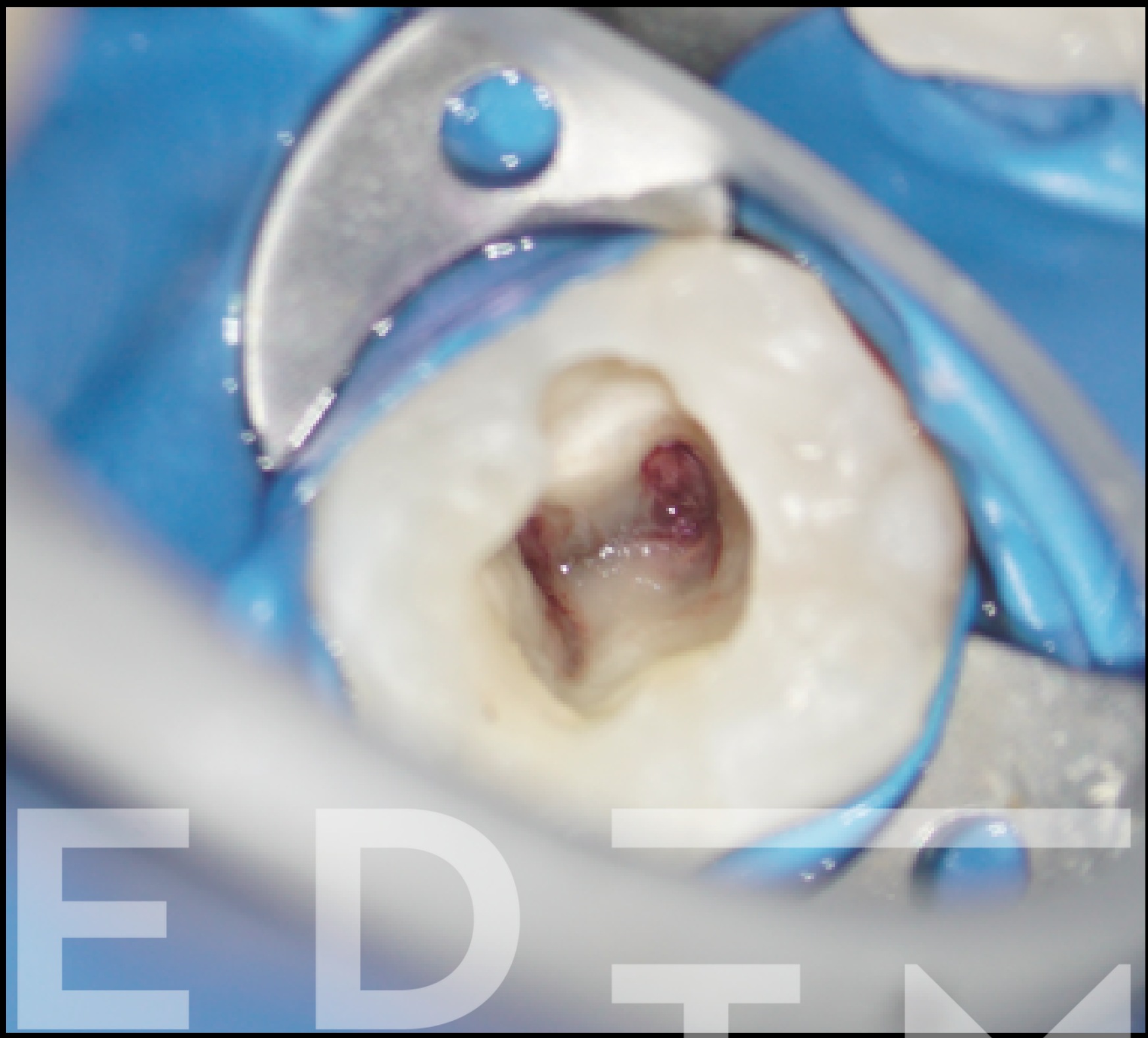

EDTM

Connaissez-vous le temps idéal d'obtention de l'hémostase, autorisant le coiffage radiculaire ?

Non ?



NOUS NON PLUS !

Il n'y a aucun consensus à ce jour dans la littérature

Received: 27 August 2024 | Accepted: 19 January 2025

DOI: 10.1111/iej.14205

ORIGINAL ARTICLE

INTERNATIONAL ENDODONTIC JOURNAL | WILEY

The outcome of full and deep pulpotomy in teeth with extremely deep carious lesion and symptomatic irreversible pulpitis: A non-inferiority randomized controlled trial

Aaqib Shah | **Amritha PV** | **Sidhartha Sharma** | **Vijay Kumar** | **Amrita Chawla** | **Ajay Logani**

Division of Conservative Dentistry and Endodontics, Centre for Dental Education and Research, All India Institute of Medical Sciences, New Delhi, India

Correspondence
Vijay Kumar, Division of Conservative Dentistry and Endodontics, Centre for Dental Education and Research, All India Institute of Medical Sciences, New Delhi, India.
Email: kumarvijay29@gmail.com

Abstract

Aim: To compare the outcome of full and deep pulpotomy performed in mature permanent teeth with extremely deep carious lesion and symptomatic irreversible pulpitis.

Methodology: This parallel-group, double-blind, non-inferiority randomized controlled trial was conducted after ethical clearance. Patients with mature permanent teeth with extremely deep carious lesion and diagnosis of symptomatic irreversible pulpitis were recruited. Teeth were randomly allocated to two study groups, i.e. Group I: full pulpotomy (excision of pulp tissue up to the level of root canal orifices) and Group II: deep pulpotomy (excision of radicular pulp tissue 2–3 mm apical to root canal orifices). Haemostasis was achieved using cotton pellet moistened with 2.5% NaOCl for up to 10 min. Mineral trioxide aggregate was used as a pulp capping agent and teeth were restored in the same visit with resin composite. Outcome assessment was performed at 12-month follow-up based on clinical and radiographic evaluation. The success rate was determined by intention-to-treat (ITT) and per-protocol (PP) analysis. Two sample *t*-tests were used to compare the time taken to achieve haemostasis and determine its association with treatment outcome.

Results: A total of sixty teeth received treatment in both study groups. The bleeding time was significantly more in Group I (6.13 ± 1.59 min) compared to group II (5.23 ± 1.22 min) ($p < .0171$). The recall rate was 86.6% at study end point when fifty-two teeth were analysed at 12-month follow up. The success rate was 88.46% and 92.30% for per protocol analysis and 76.67 and 80% for ITT analysis for Group I and Group II, respectively, without any statistically significant difference ($p = .610$). The absolute risk difference between each treatment was within the 10% non-inferiority limit. There was no statistically significant association between time taken to achieve haemostasis and treatment outcome in both study groups.

Conclusions: There was no significant difference between full and deep pulpotomy techniques, with respect to achievement of haemostasis and treatment outcome for management of teeth with extremely deep caries and irreversible pulpitis.

KEYWORDS

extremely deep caries, minimally invasive endodontics, pulpitis, pulpotomy, vital pulp treatment

© 2025 British Endodontic Society. Published by John Wiley & Sons Ltd





EDTM

EDTM

endodontie.paris