CAS CLINIQUE

27



EDTM

Pulpe précédemment traitée
Parodontite apicale asymptomatique



RVG6200

ENDO TIM

Nous devinons un instrument fracturé.
Racine fusionnée ?
1 seul canal ?

CETTE COUPE CONE BEAM NOUS MONTRE PLUTÔT 2 CANAUX !

Et c'est dans le canal palatin, oblitéré, que se trouve l'instrument fracturé.

Et la clinique, sous microscope, nous en fait découvrir un 3e



ED TM

Alors est-ce-que ça veut dire que nous l'avions loupé au cone beam ?

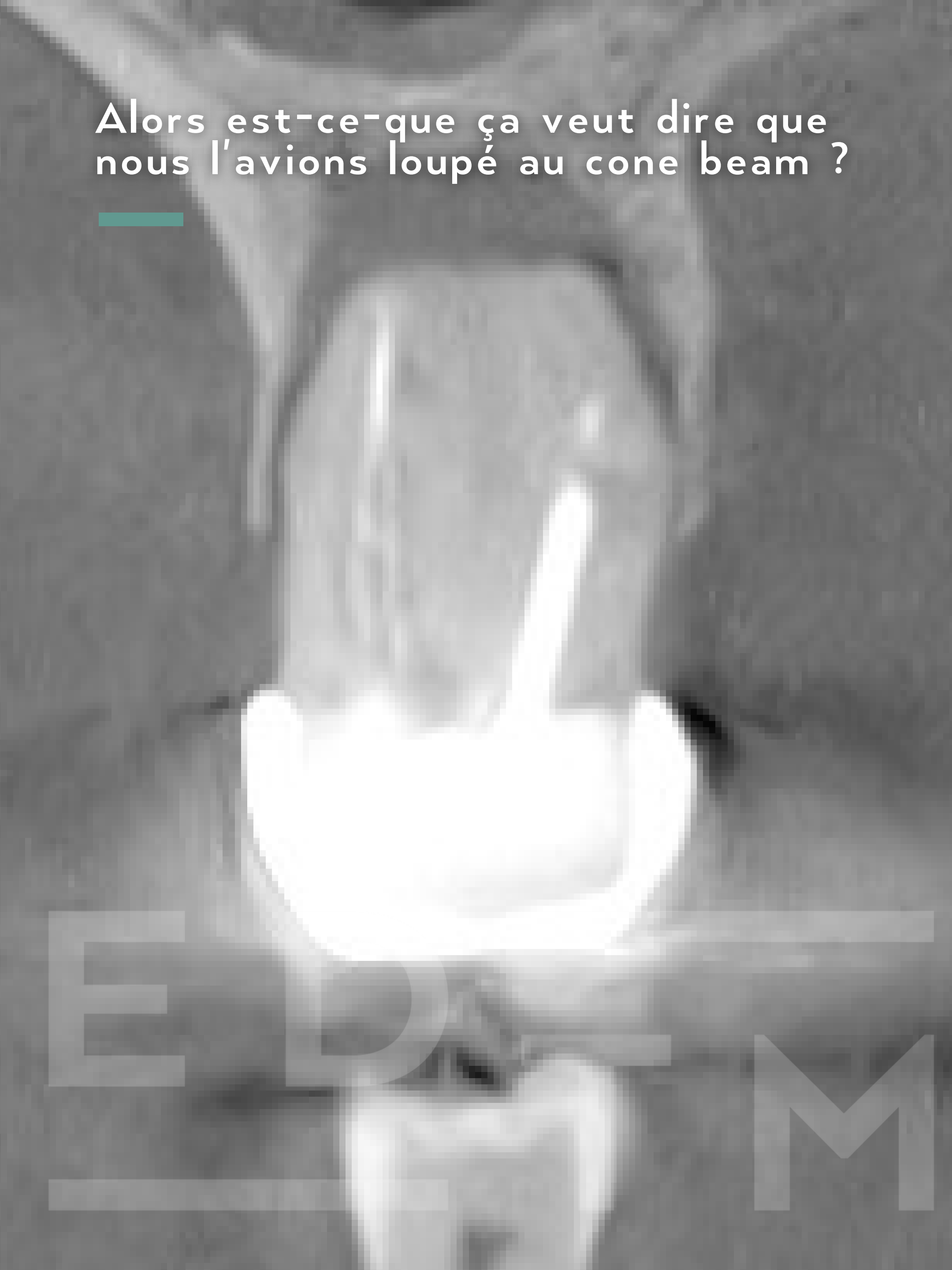

Non ! Ca veut dire qu'un canal peut ne pas être visible radiographiquement, même à la 3D !

L'observation clinique sous microscope est nécessaire à la lecture de l'anatomie, mais peut de ne pas être suffisante.

L'observation radiographique à la 3D peut devenir nécessaire à la lecture de l'anatomie, mais peut également de ne pas être suffisante.







C'est la combinaison des 2 qui nous permettra d'optimiser les chances de cartographier et de traiter toute l'anatomie canalaire.



Parker, J., Mol, A., Rivera, E. M., & Tawil, P. (2017). CBCT uses in clinical endodontics: The effect of CBCT on the ability to locate MB2 canals in maxillary molars. International Endodontic Journal, 50(12), 1109–1115.

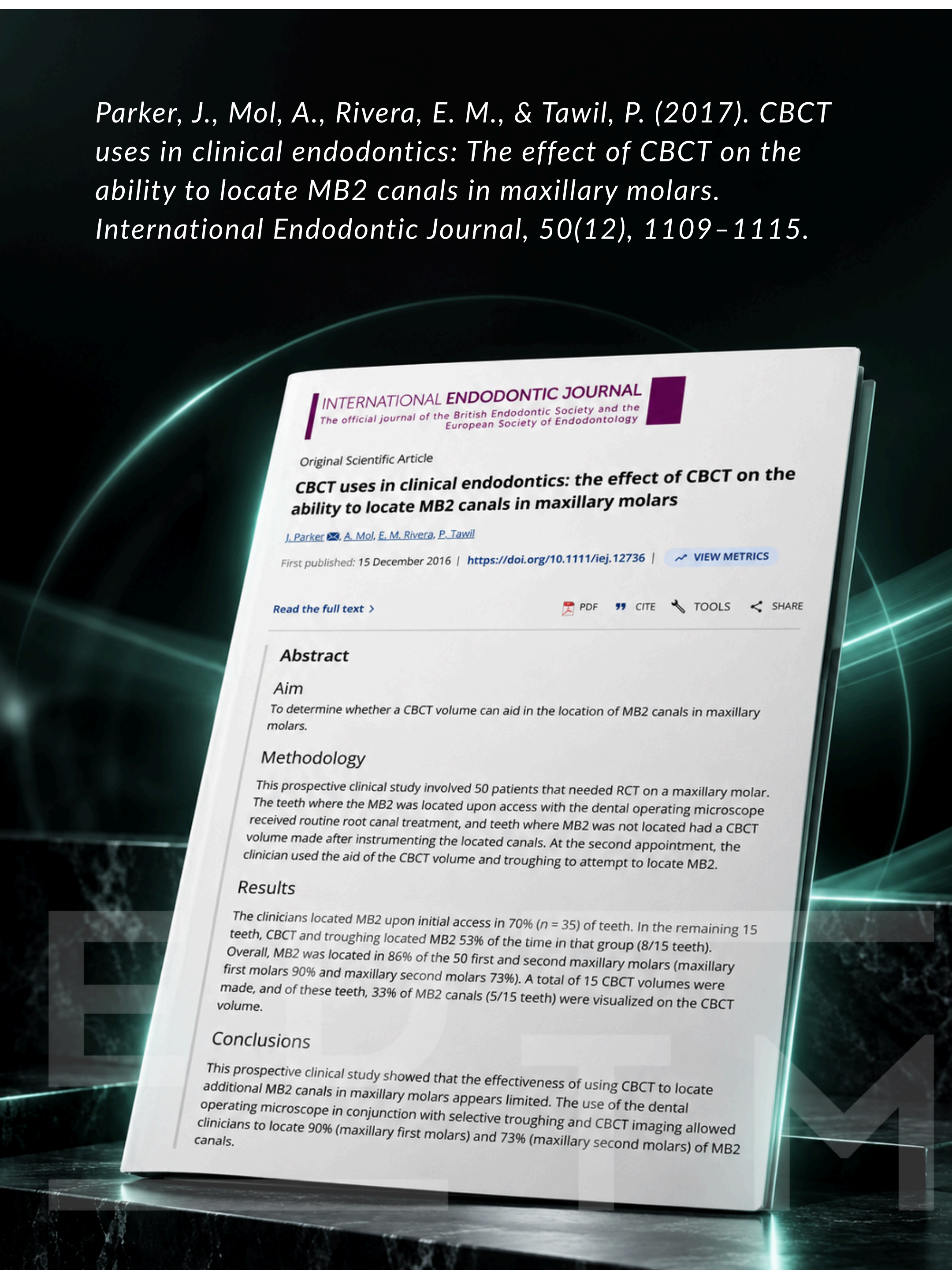

INTERNATIONAL ENDODONTIC JOURNAL
The official journal of the British Endodontic Society and the European Society of Endodontology

Original Scientific Article

CBCT uses in clinical endodontics: the effect of CBCT on the ability to locate MB2 canals in maxillary molars

J. Parker, A. Mol, E. M. Rivera, P. Tawil

First published: 15 December 2016 | https://doi.org/10.1111/iej.12736 | VIEW METRICS

Read the full text > PDF CITE TOOLS SHARE

Abstract

Aim

To determine whether a CBCT volume can aid in the location of MB2 canals in maxillary molars.

Methodology

This prospective clinical study involved 50 patients that needed RCT on a maxillary molar. The teeth where the MB2 was located upon access with the dental operating microscope received routine root canal treatment, and teeth where MB2 was not located had a CBCT volume made after instrumenting the located canals. At the second appointment, the clinician used the aid of the CBCT volume and troughing to attempt to locate MB2.

Results

The clinicians located MB2 upon initial access in 70% (n = 35) of teeth. In the remaining 15 teeth, CBCT and troughing located MB2 53% of the time in that group (8/15 teeth). Overall, MB2 was located in 86% of the 50 first and second maxillary molars (maxillary first molars 90% and maxillary second molars 73%). A total of 15 CBCT volumes were made, and of these teeth, 33% of MB2 canals (5/15 teeth) were visualized on the CBCT volume.

Conclusions

This prospective clinical study showed that the effectiveness of using CBCT to locate additional MB2 canals in maxillary molars appears limited. The use of the dental operating microscope in conjunction with selective troughing and CBCT imaging allowed clinicians to locate 90% (maxillary first molars) and 73% (maxillary second molars) of MB2 canals.

EDTM

endodontie.paris

