LITTÉRATURE

PULPITE RÉVERSIBLE OU IRRÉVERSIBLE ?

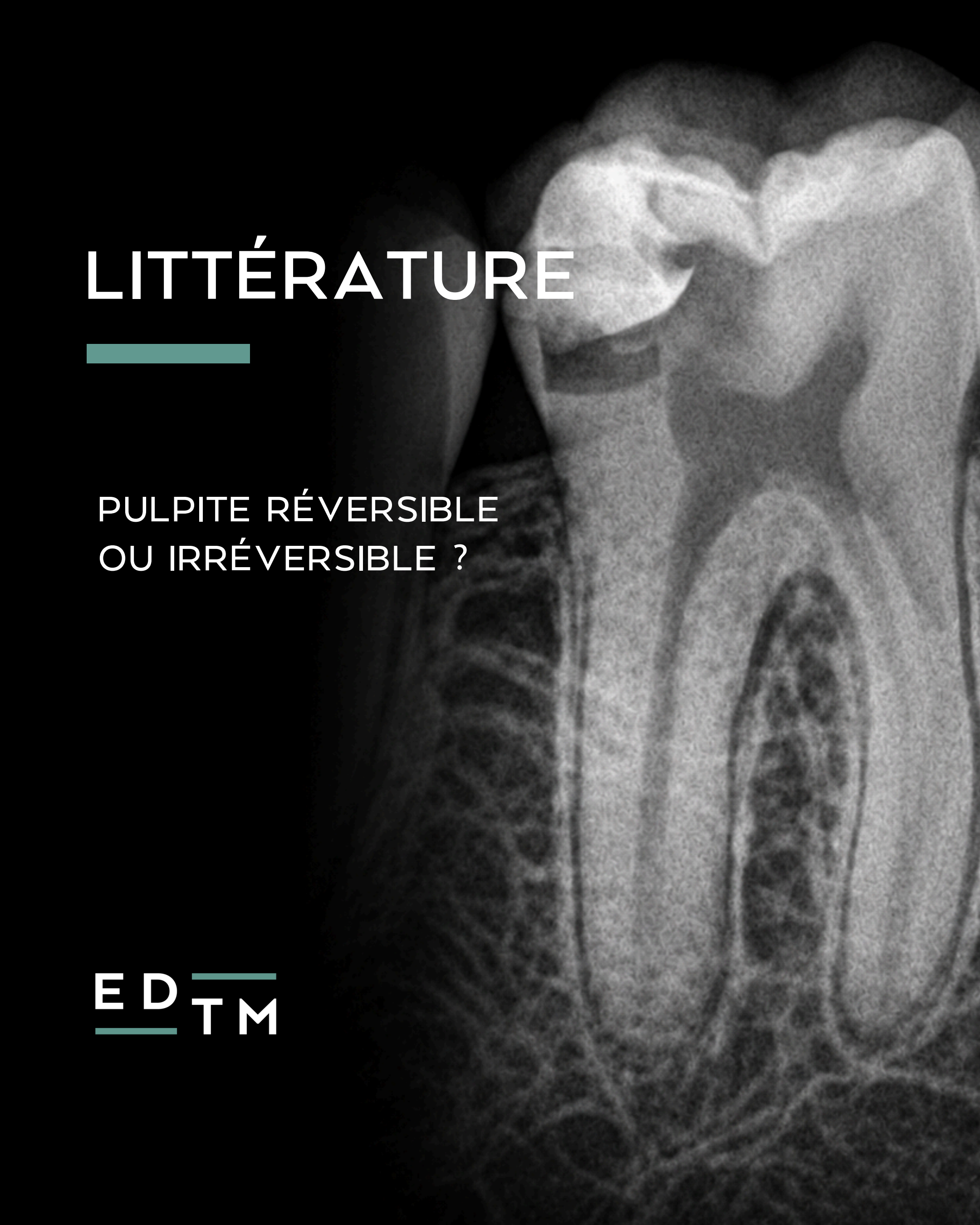

EDTM

EDTM

endodontie.paris

La patiente est très sensible au froid avec un test au froid >20sec, l'ibuprofène calme les douleurs

EDITM

✓ PULPITE IRRÉVERSIBLE



SAUF QUE LA CLASSIFICATION A CHANGÉ

Nouvelle classification endolight (Wolters et al 2017)

INTERNATIONAL ENDODONTIC JOURNAL

EDITORIAL

doi:10.1111/iej.12793

Minimally invasive endodontics: a new diagnostic system for assessing pulpitis and subsequent treatment needs

W. J. Wolters[1], H. F. Duncan[2], P. L. Tomson[3], I. E. Karim[4], G. McKenna[5], M. Dorn[6], L. Stangvaltaite[7] & L. W. M. van der Sluis[1]

[1]Center of Dentistry and Oral Hygiene, University Medical Center Groningen, Groningen, The Netherlands, [2]Division of Restorative Dentistry & Periodontology, Dublin Dental University Hospital, Trinity College Dublin, Dublin, Ireland; [3]College of Medical & Dental Sciences, The University of Birmingham School of Dentistry, Birmingham; [4]Centre for Dentistry, School of Medicine, Dentistry and Biomedical Sciences, Queen's University Belfast, Belfast; [6]Centre for Public Health, Queen's University Belfast, Belfast; [6]School of Oral and Dental Sciences, Bristol Dental School, Bristol, UK; and [7]Department of Clinical Dentistry, Faculty of Health Sciences, UIT The Arctic University of Norway, Tromsø, Norway

Aim

To introduce a new way of thinking about the inflamed pulp. We want to highlight that there is reversibly inflamed tissue in pulps that are currently diagnosed as irreversibly inflamed. This implies that the currently employed terminology may not reflect the actual inflammatory status of pulps evaluated clinically. We therefore propose and introduce a new diagnostic system with new terminology to highlight the healing potential of the pulp. This also implies that current treatment strategies are evaluated and revised to maintain pulp vitality with associated benefits.

Introduction

In the majority of cases of mature teeth diagnosed with irreversible pulpitis or apical periodontitis, root canal treatment is the therapy of choice to save the tooth. Inherent in this procedure is loss of dental hard tissue and subsequent weakening of the treated tooth (Öktem 2006, Al-Omiri *et al.* 2010), making them more prone to fracture (Rech *et al.* 1989, Al-Omiri *et al.* 2010). Irreversible pulp inflammation and apical periodontitis indicate a dental infectious disease related to the presence of microorganisms in and/or outside the root canal system (Haapasalo *et al.* 2011). To resolve apical periodontitis and more advanced pulpal disease, the conventional treatment is removal of the complete pulp (root canal treatment) with the aim to reduce the number of bacteria in the root canal system which cause infection. However, cross-sectional research in the Netherlands has shown that around forty per cent of root filled teeth are associated with an apical radiolucency when examined using two-dimensional dental radiographs (Peters *et al.* 2011), indicating failure of the procedure, as only a small proportion of apical radiolucencies remain visible as fibrotic healing scars (Nair *et al.* 1999, Love & Firth 2009). This trend is seen worldwide (Wu *et al.* 2009). Furthermore, endodontically treated teeth without visible radiographic signs of apical periodontitis can still be infected (Molander *et al.* 1998, Ricucci *et al.* 2014). Therefore, the actual failure rate of standard root canal treatments performed in general practice is significantly higher than expected. Furthermore, these treatments are lengthy and costly and are often subject to retreatment (Pigdor 2002). Less invasive alternative strategies could be used to treat pulpitis and increase the success of endodontic procedures beyond the improvement of the 'tools and gadgets' used during conventional root canal treatment.

As new insights in pulp biology have been gained, recent clinical research on vital pulp therapy now provides options for developing new biologically

Correspondence: W.J. Wolters, Center of Dentistry and Oral Hygiene, University Medical Center Groningen, Antonius Deusinglaan 1, 9713 AV Groningen, The Netherlands (e-mail: w.j.wolters@umcg.nl)

© 2017 International Endodontic Journal. Published by John Wiley & Sons Ltd

D'après ce système de gradient diagnostic pulpaire, les signes cliniques évoquent ici une pulpite modérée

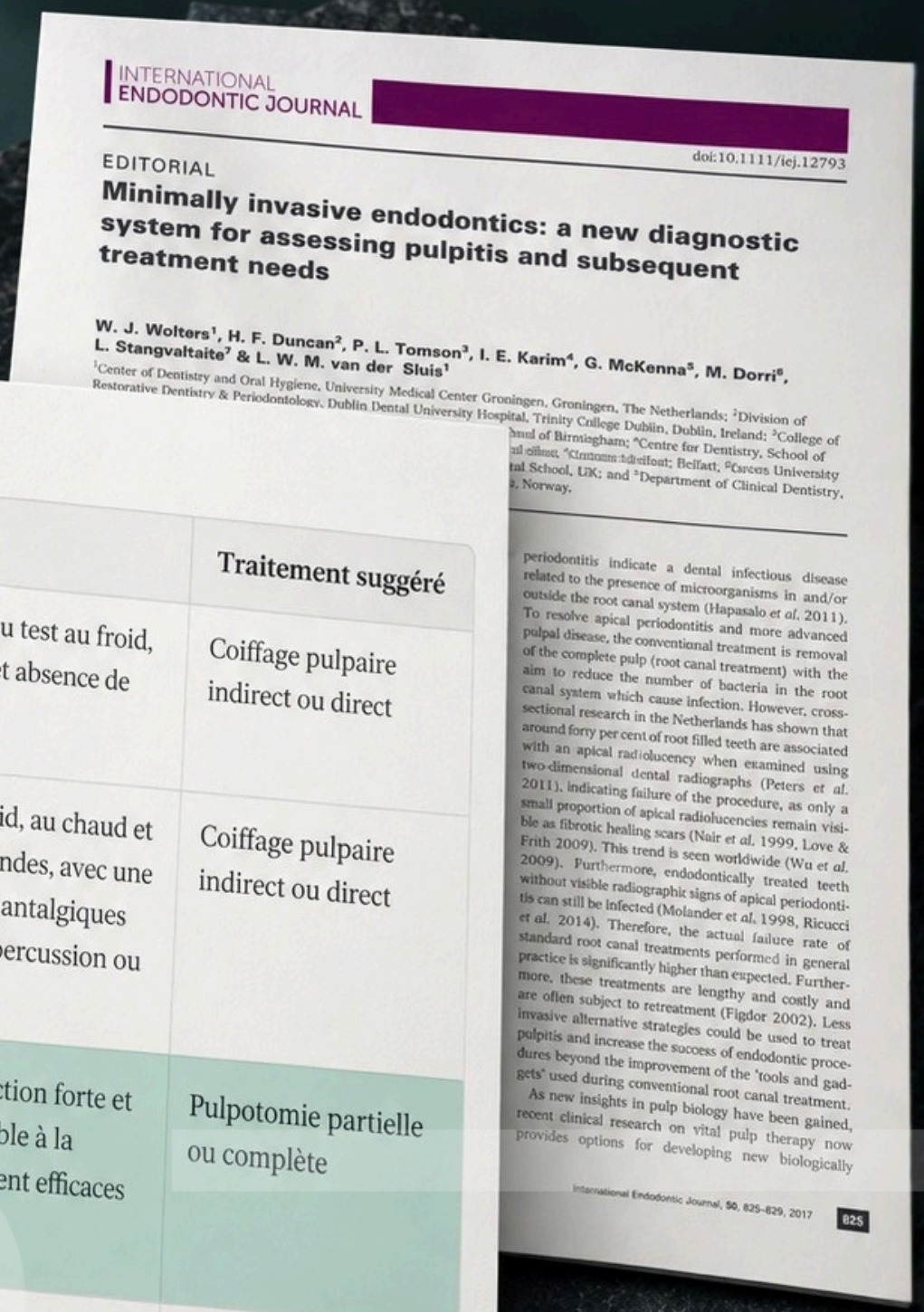

INTERNATIONAL ENDODONTIC JOURNAL

doi:10.1111/iej.12793

EDITORIAL

Minimally invasive endodontics: a new diagnostic system for assessing pulpitis and subsequent treatment needs

W. J. Wolters[1], H. F. Duncan[2], P. L. Tomson[3], I. E. Karim[4], G. McKenna[5], M. Dorri[6], L. Stangvaltaite[7] & L. W. M. van der Sluis[1]

[1]Center of Dentistry and Oral Hygiene, University Medical Center Groningen, Groningen, The Netherlands; [2]Division of Restorative Dentistry & Periodontology, Dublin Dental University Hospital, Trinity College Dublin, Dublin, Ireland; [3]College of ... of Birmingham; [4]Centre for Dentistry, School of ... Belfast; [5]Queens University ... School, UK; and [6]Department of Clinical Dentistry, ... Norway.

periodontitis indicate a dental infectious disease related to the presence of microorganisms in and/or outside the root canal system (Hapasalo *et al.* 2011). To resolve apical periodontitis and more advanced pulpal disease, the conventional treatment is removal of the complete pulp (root canal treatment) with the aim to reduce the number of bacteria in the root canal system which cause infection. However, cross-sectional research in the Netherlands has shown that around forty per cent of root filled teeth are associated with an apical radiolucency when examined using two-dimensional dental radiographs (Peters *et al.* 2011), indicating failure of the procedure, as only a small proportion of apical radiolucencies remain visible as fibrotic healing scars (Nair *et al.* 1999, Love & Frith 2009). This trend is seen worldwide (Wu *et al.* 2009). Furthermore, endodontically treated teeth without visible radiographic signs of apical periodontitis can still be infected (Molander *et al.* 1998, Ricucci *et al.* 2014). Therefore, the actual failure rate of standard root canal treatments performed in general practice is significantly higher than expected. Furthermore, these treatments are lengthy and costly and are often subject to retreatment (Figdor 2002). Less invasive alternative strategies could be used to treat pulpitis and increase the success of endodontic procedures beyond the improvement of the 'tools and gadgets' used during conventional root canal treatment.

As new insights in pulp biology have been gained, recent clinical research on vital pulp therapy now provides options for developing new biologically

Catégorie	Signes et symptômes cliniques	Traitement suggéré
Pulpite initiale	Réponse accrue mais non prolongée au test au froid, absence de sensibilité à la percussion et absence de douleur spontanée	Coiffage pulpaire indirect ou direct
Pulpite légère (mild)	Réaction intensifiée et prolongée au froid, au chaud et au sucré, pouvant durer jusqu'à 20 secondes, avec une possible sensibilité à la percussion. Les antalgiques restent efficaces contre la douleur à la percussion ou spontanée	Coiffage pulpaire indirect ou direct
Pulpite modérée	Symptômes plus marqués, avec une réaction forte et prolongée au froid, une sensibilité possible à la percussion, et des antalgiques modérément efficaces contre la douleur	Pulpotomie partielle ou complète
Pulpite sévère	Réaction douloureuse importante au chaud ; les antalgiques n'apportent que peu de soulagement, le patient ne peut pas dormir la nuit à cause de la douleur, et une sensibilité à la percussion est observée	Pulpotomie complète, ou en cas d'hémorragie pulpaire persistante, extirpation vitale (pulpectomie)

EDTM

endodontie.paris